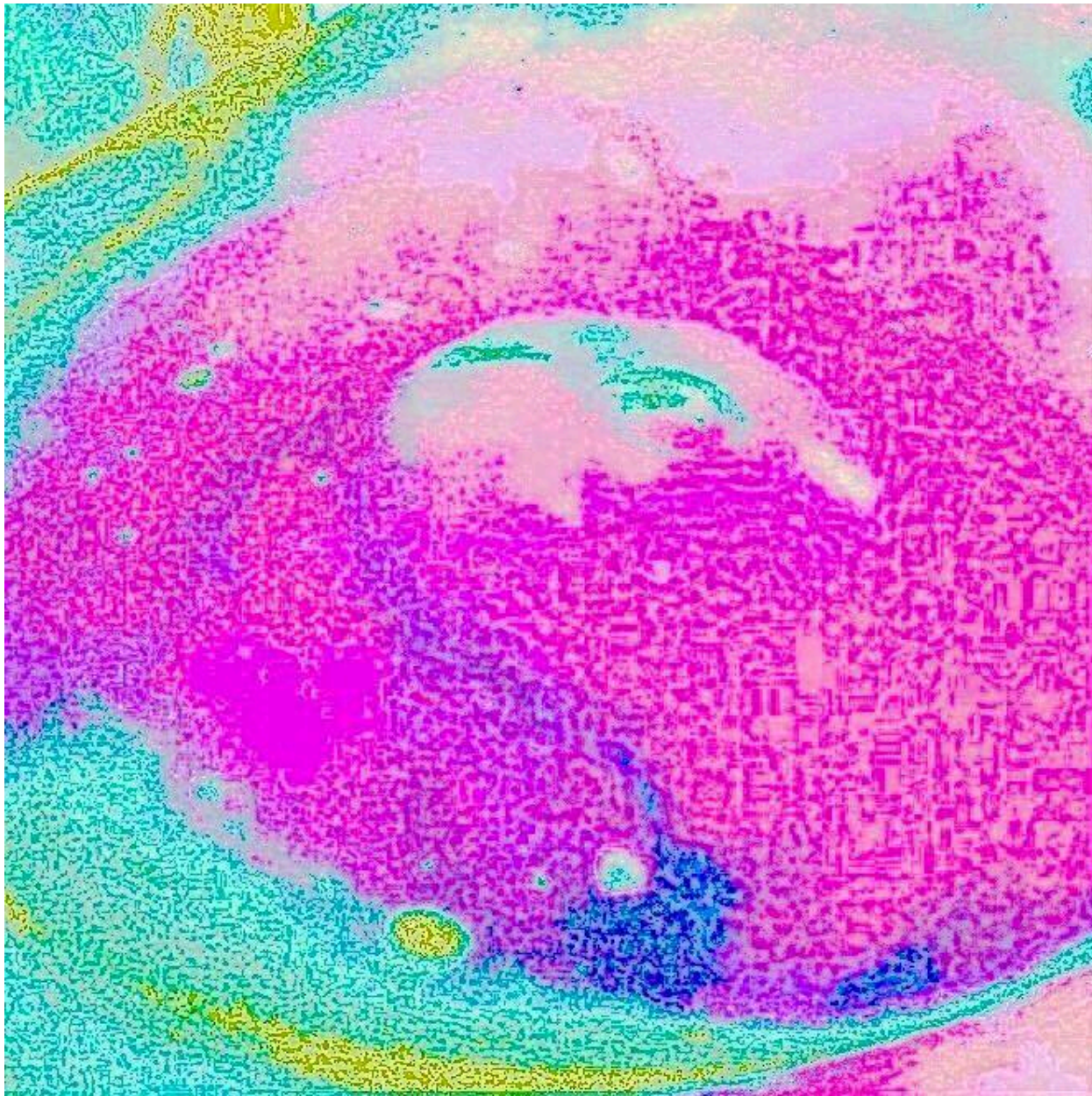


NIDI... NON INVASIVE DIAGNOSTIC IMAGING ...Looking at VEINS in the Breast...Case study Monday October 17th, 2016 10:37 am...

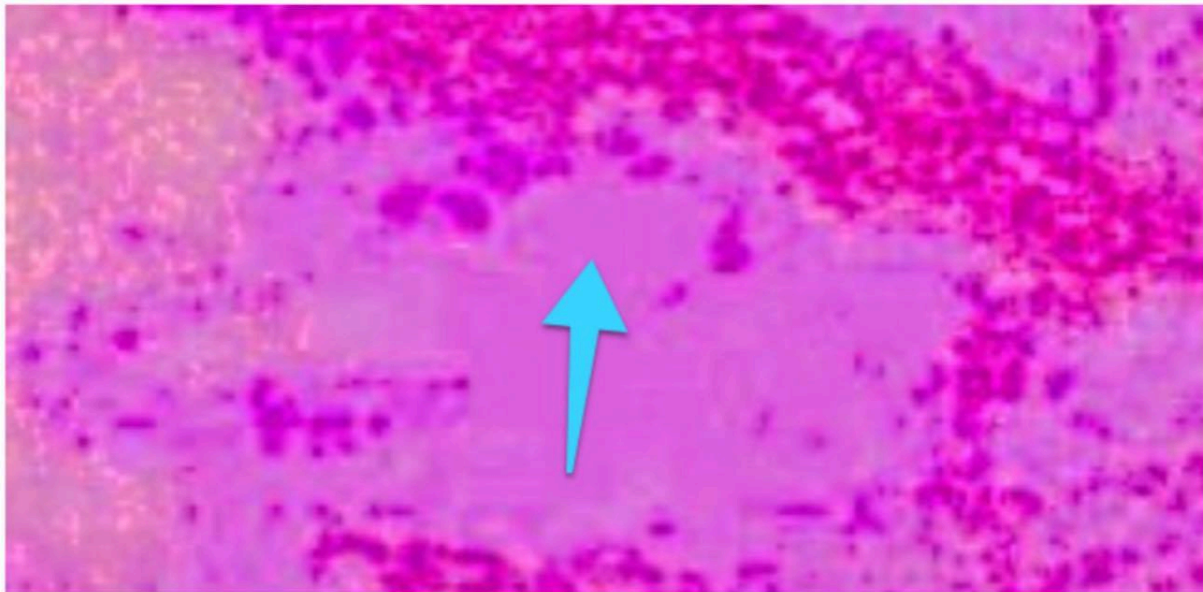
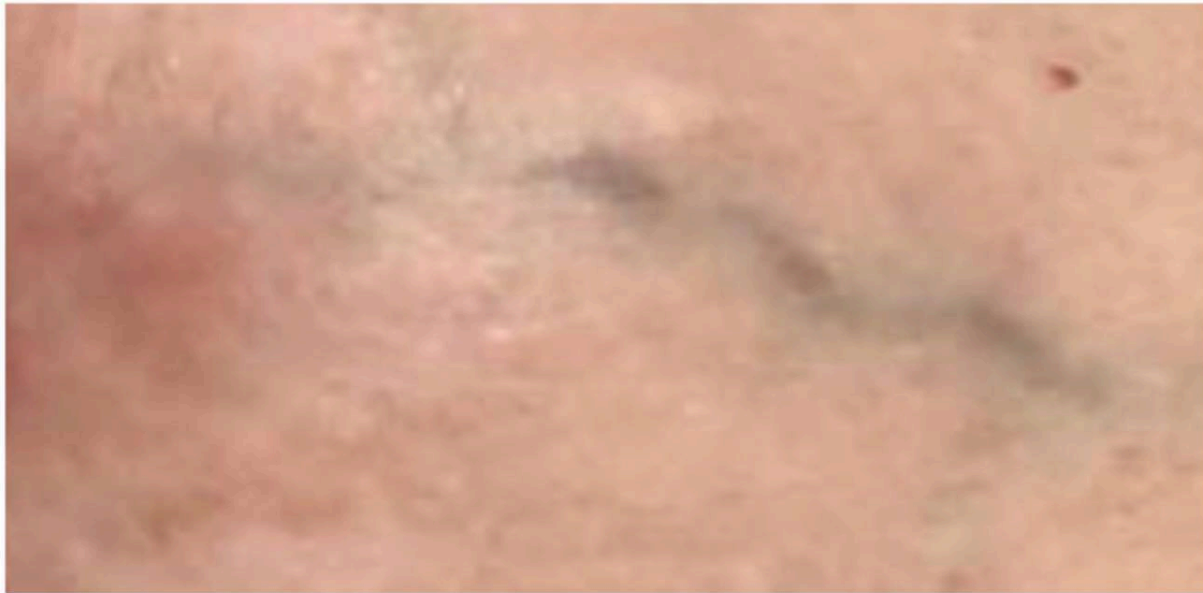

Sari Grove

NIDI... NON INVASIVE DIAGNOSTIC IMAGING ...Looking at VEINS in the Breast...Case study Monday October 17th, 2016 10:37 am...

So purple in Lunapic is Phosphorus which is a cancer marker...So...What we are seeing above in left breast, is it Phosphorus in the vein feeding the cyst? Also...Does this mean that dark blue spots are benign cysts? If so, is dark blue a marker for oil! Carbon(is oil on the chart)...No, wait, if dark blue is water Hydrogen because most cysts are fluid filled, then are we seeing a water filled cyst being fed Phosphorus & that could turn malignant if we don't catch it? Eat your Coriander seeds & Cilantro leafs & drink your Licorice root...

NIDI... NON INVASIVE DIAGNOSTIC IMAGING ...Looking at VEINS in the Breast...Case study Monday October 17th, 2016 10:37 am...



Sari Grove

NIDI... NON INVASIVE DIAGNOSTIC IMAGING ...Looking at VEINS in the Breast...Case study Monday October 17th, 2016 10:37 am...


These are two pics of somebody else who has big veins...Yes...What we are seeing in Lunapic is the Phosphorus travels along veins...So the parasite is swimming in our vein, which then seeks out a water filled cyst, & settles in when it gets there, & forms what we call a tumour but is really a tiny parasite, nesting inside a water filled cyst, eating & growing...Feeding off the food in the cyst...I think you mean cholesterol when you say oil- fat, or Aluminum on the chart...

[Sari Grove](#)

Yellow Calcium also is apparent along vein lines- must be this clogs them up in the first place so lumps form(Calcium is progesterone like from birth control)(high dose contraceptives also have an estrogen component- prostitutes/ lap dancers/strippers use high dose)...

Estrogen is Phosphorus

NIDI... NON INVASIVE DIAGNOSTIC IMAGING ...Looking at VEINS in the Breast...Case study Monday October 17th, 2016 10:37 am...



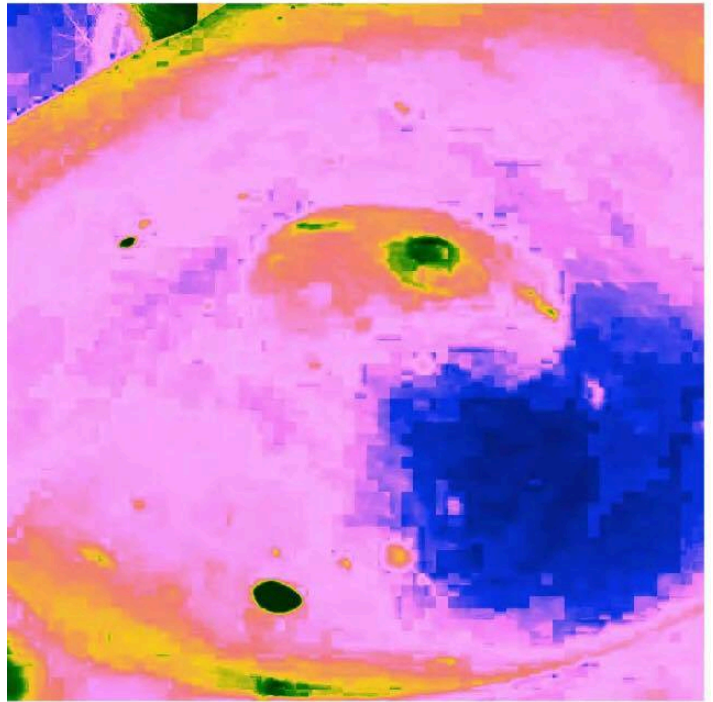
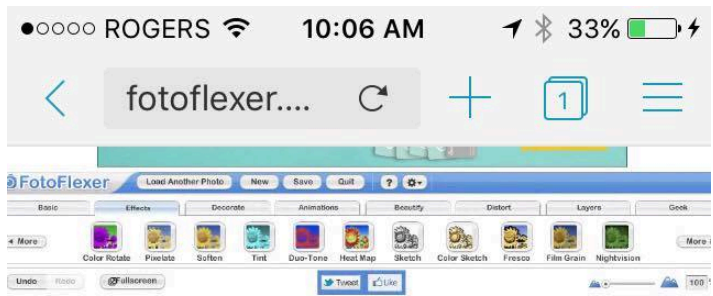
NIDI... NON INVASIVE DIAGNOSTIC IMAGING ...Looking at VEINS in the Breast...Case study Monday October 17th, 2016 10:37 am...

[Sari Grove](#)

Sorry slight size change in picture, iPhone saving is by screenshot, can't save manually...Pixlr above shows red Hydrogen inflammation they call it...

Hydrogen does follow vein line shape too...

NIDI... NON INVASIVE DIAGNOSTIC IMAGING ...Looking at VEINS in the Breast...Case study Monday October 17th, 2016 10:37 am...



NIDI... NON INVASIVE DIAGNOSTIC IMAGING ...Looking at VEINS in the Breast...Case study Monday October 17th, 2016 10:37 am...

10:08

[Sari Grove](#)

Ok the pink colour, Not the pale pink that is everywhere, but the subtly Darker pink, That is Iron...Iron is following the vein line too...Iron is red blood cells basically...